



FURTHER EVALUATION OF FIELD EFFICACY OF SCABICUR® LOTION IN THE CONTROL OF MANGE AND ECTOPARASITES IN DOMESTIC ANIMALS IN NIGERIA

DOGO*, G.I., OGUNSAN, E. A., TANKO, T.J., KAMANI, J., TAFARKI, A.E., NNABUIFE, H.E and PETERS J.

Parasitology Division, National Veterinary Research Institute, Vom, Nigeria.

*Corresponding author: Email: gdogo@yahoo.com

SUMMARY

The field efficacy of topical application of Scabicur® lotion was further assessed in 558 domestic animals comprising of Cattle, Sheep, Goats and Pigs naturally infested with mange and ectoparasites. The study was performed to answer the research question whether Scabicur® lotion preparation can be a cheaper alternative against sarcoptic mange and ectoparasites in livestock. Evaluations included physical examination for clinical signs of *Sarcoptes scabiei* infestations, examination of samples of skin scrapings for determination of mite(s) pre and post- treatment, collection and identification of ectoparasites (Ixodid ticks) burden. Affected animals were treated topically for 7 days consecutively using depending on size 10-20mls of 0.5% w/v of Scabicur® lotion per animal. The treatment resulted in clinical improvement within 21 days post initial topical application. There was complete disappearance of signs of scabies such as pruritis, alopecia, scratching on the wall and disappearance of scabs or ticks in randomly selected animals in the herds. The ticks were all dead after 7 days of topical application. Scabicur® lotion can be used as an adjunct in the management and control of scabies, ectoparasitism and other related maladies in domestic animals since the current scabicides and acaricides are relatively expensive, toxic to animals as well as constituting environmental hazards.

Keywords: Field Efficacy, Scabicur, Mange, Ectoparasites, Animals.

INTRODUCTION

Mange is a contagious skin condition affecting humans and animals with global distribution. It is caused by mite species of the genera *Sarcoptes*, *Demodex*, *Chorioptes*, *Psoroptes*, *Cheilytiella* amongst others. Some of the mites burrow into the lower stratum corneum of the skin (1, 2, and 3). Infection caused by *Sarcoptes scabiei* mite elicits marked irritation, intense itching, coagulation, and encrustation of the skin (4 and 5). Sarcoptic mange is a common ectoparasitic disease of domestic animals especially in pigs raised under poor management conditions. Endemic and enzootic levels of human and animal scabies respectively, continue to occur despite the availability of various therapies (5, 6, and 7). Ticks are ectoparasites of wild, domestic animals, birds, reptiles and humans, and have been known to transmit pathogens such as fungi, viruses, bacteria and protozoans. In terms of ability to transmit diseases, ticks are considered as second to mosquitoes as vectors of human diseases, and the major vectors of most animal diseases. Total losses in animals due to tick infestation have been estimated to be approximately US\$7 billion annually, and with 80% of

the world cattle population at risk from ticks and tick – borne diseases (8). Their worldwide distribution most especially in tropical Africa have negative impact on animals by causing direct damage to hides and skin and also low productivity, anaemia, toxæmia and tick paralysis, thus constraining the development of a viable livestock industry. Ixodid ticks attach to the skin of their hosts and remain there for several days, engorging on blood and intermittently passing salivary secretions into the host. Several species of ixodid ticks transmit pathogenic microorganisms along with their saliva into the host, and these tick borne diseases such as cowdriosis, babesiosis, anaplasmosis and theileriosis are of great economic importance, particularly in cattle in sub-tropical and tropical areas. Common chemo-therapeutics in use against mites and ectoparasites include coumaphos, asuntol, lindane, toxaphane, chlorodane, benzene hexachloride (BHC), amitraz, alugan, chlorinated hydrocarbons and ivermectins which are usually relatively expensive. *Sarcoptic scabiei* var *caprae* infection of goats can be difficult to treat in that it needs frequent and careful application of chemical drugs (7). There is a need to look inward to provide local alternatives that will be affordable, available, relatively less toxic and

environmentally friendly. Scabicur® lotion, a preparation by Parasitology Division, National Veterinary Research Institute, Vom, Nigeria satisfy these criteria. It was formulated for the management and control of scabies in animals and later found useful in humans. The drug is undergoing the process of licensing for general use. To the authors' knowledge, there is no further field efficacy information regarding Scabicur® lotion used in domestic animals with Sarcoptic mange and ectoparasitism. There is no other known report on the therapeutic efficacy of Scabicur® lotion on Sarcoptic mange of farm animals. There is no documented information on the pharmaceutical action of Scabicur® lotion yet. The purpose of this study was to further assess the field efficacy of Scabicur® lotion in the treatment of Sarcoptic mange and control of ticks in naturally infested domestic animals.

MATERIALS AND METHODS

A total of 558 domestic animals comprising of 48 cattle (23 Sokoto Gudale, 25 White Fulani), 10 Pigs, 200 Sheep and 300 Goats naturally infested with ectoparasites namely *Amblyomma variegatum*, *Boophilus decoloratus*, *Sarcoptes scabiei*, *Hyalomma spp* were used. On close examination of the 200 sheep and 300 goats in Bwari Farm, Abuja, there was generalized dermatitis, alopecia and encrustation of the skin of about 30 days duration. The animals experienced intense pruritis with denuded areas of skin. Due to the presence of ticks, clinical signs and characteristics of the lesions, ectoparasitism was suspected. Ten piglets in a Piggery farm at Dadin Kowa, Jos, on examination were seen rubbing their bodies against the walls of the pen, had decreased appetite, loss of hairs and stunted growth, dermatitis, and paint brush appearance of the hair, scabs and scales on the body of the piglets were also observed. Skin scrapings were taken and digested in 10% potassium hydroxide and examined under the microscope. Scabicur® lotion was applied on the skin for one week.

A cattle herd of 48 animals belonging to the Federal College of Land and Soil Resources (FCLSR), Jos Plateau State reported to have matted hair, loss of hair, scabs, circumscribe elevation of the skin and ticks infestation were visited. History revealed the animals were treated with Dermacur® and Ivermectin but some of the lesions reoccurred.

Composition of Scabicur® Lotion

The composition and physical properties of Scabicur® lotion is made up of the following ingredient based on the public analyst's certificate:- Colour is light brown, odour is fragrant odour, and refractive index is 1.4560 bet. 1.453 – 1.459, Specific gravity is 0.9004 bet. 0.898-0.9907 and the active ingredient is made up of Ferric oxide 0.4% stated, amount found 0.385 which is 96.3% label strength and Sulphur 3.5% stated, amount found 3.48 which is 99.4% label strength.

Indication

Scabicur® lotion is used for the prevention and treatment of a wide range of parasitic infections (scabies, myiasis, lousiness, ticks etcetera), fungal infections and bacterial infections. The dosage form of the Scabicur® is in lotion form applied to the affected areas and there is no known side effect or irritation on the skin.

Drug application

Using soaked, soft paint brush, Scabicur® lotion was applied on the affected areas for 7 days un-interrupted daily in the owner's residence where the goat was kept in a shed. The efficacy of Scabicur® lotion was evaluated on the basis of absence of mites and disappearance of lesions such as pruritus, dermatitis, erythema, scaling/crusting, papules, alopecia and pyoderma. After forty eight hours of continuous treatment, the aforementioned signs subsided. Fourteen days post treatment the goat was examined for mites and it was negative and re-growth of hair on the affected parts of the skin was established (Fig. 1b). There was no side effect observed on the goat during and after treatment and there was no report on any relapse of the disease since recovery.

RESULTS

Following the application of Scabicur® lotion literally on the skin with soft paint brush for seven days, scabs were off the animal's skin and ulcers began to heal on the third day post treatment. Definitive diagnosis of mange was confirmed by microscopic examination of skin scrapings from the affected sites. Skin scrapings were prepared with a 10% solution of Potassium hydroxide to eliminate debris on the slide and ease the examination by light microscopy. Eggs, larvae and adult stages of mites were identified as *Sarcoptes scabiei var caprae*, (11).

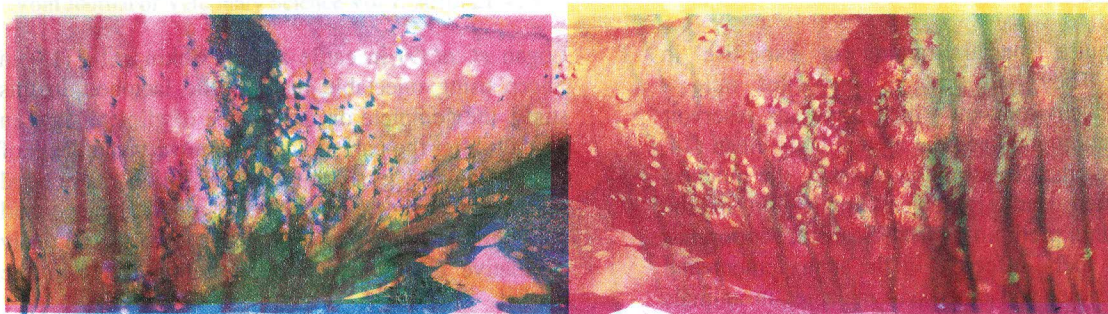


Figure 1a and b. Showing nodular lesions of the affected site of the skin of a cow and scabs of *Dermatophilus congolense* before (a) and after (b) treatment.

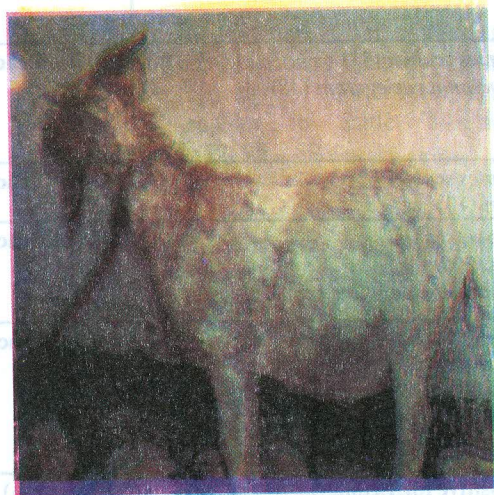


Figure 2a and b. Mange infested adult female Goat before (a) and after (b) treatment.

DISCUSSION

Sarcoptic mange is an economically important parasitic disease in mammals (6) with the life cycle of *Sarcoptes scabiei* completed within 10 – 14 days usually (17). Thus, effective treatment geared towards total elimination of the parasite is paramount. Treatment of the disease especially in animals can be difficult due to resistance and the high cost of available drugs. Although there are many acaricidal products such as the organophosphates and pyrethroid insecticides; and compounds such as amitraz available

for the treatment of mange in domestic animals. These are applied as wash, dusting, dip and sprays but Sarcoptic mange remains a problematic disease in domestic animals (10, 11, 12). The current trend in the treatment of Sarcoptic mite infestations is the use of several systematically acting macrocyclic lactones though topical treatment still remains probably the best route in the control of Sarcoptic mange (9). The advantages of topically applied drugs over injectable microcyclic lactones (ivermectin, doramectin and moxidectin) are that, they are relatively less expensive;

do not require special training or expertise in application. They help in the control of mite – contaminated environment which serves as reservoir for re-infestation and keep the animal body clean (14, 15, 16). Since the disease is on the skin, the quickest and the fastest route is topical application of the Scabicides. In a preliminary trial, Scabicur® lotion has been shown to be effective in the management and control of scabies and other skin maladies in animals and man (13). This study is a further evaluation of Scabicur® lotion in the field which shows that on the third day of application, ticks were found dead, scabs peeled off and skin ulcers began to heal. After the seventh day of application the hair growth was noticed to have come back to normal.

The effective elimination of all stages of the infestation are comparable with results obtained by

Logan *et. al.*(9) in cattle and by Sekin *et. al.*(15) in Sheep using injectable macrocyclic lactones. In this study, the complete disappearance of clinical signs in 21 days after the parasitological recovery and death of all ticks have shown that Scabicur® lotion can be used in the effective treatment of Sarcoptic mange and control of ectoparasites in domestic animals as a ready alternative to the expensive systemic drugs in the market.

ACKNOWLEDGEMENT

The Executive Director, National Veterinary Research Institute, Vom is being appreciated for funding of the project and for permission to present research work. The authors also acknowledge the technical support of staff of the Parasitology Division of the National Veterinary Research Institute Vom Nigeria.

TABLE 1: Efficacy of Scabicur® lotion against mange and ectoparasites in domestic animals

Animal Species	Herd/ Population size	Breed	Sex/Age	No. Positive for Ectoparasites	Efficacy (%)
Cattle (Bovine)	48	Sokoto gudali (23) White Fulani (25)	Female/ Adult	<i>Sarcoptes scabiei</i> (33) <i>Amblyomma variegatum</i> (48)	100% efficacy
Pig (Porcine)	10	Landrace	Female/ Adult	<i>Sarcoptes scabiei</i> <i>Scabiei</i> (10)	100% efficacy
Sheep (Ovine)	300	Yankasa	Female/ Adult	<i>Sarcoptes scabiei</i> <i>ovinae</i> (200) <i>Hyalomma/ Boophilus spp.</i> (100)	100% efficacy
Goat (Caprine)	200	Sokoto red	Female/ Adult	<i>Sarcoptes scabiei</i> <i>Caprine</i> (80) - <i>Boophilus decoloratus</i> (90) - <i>Amblyomma Variegatum</i> (50)	100% efficacy
Animal Species	Herd/ Population size	Breed	Sex/Age	No. Positive for Ectoparasites	Efficacy (%)
Cattle (Bovine)	48	Sokoto gudali (23) White Fulani (25)	Female/ Adult	<i>Sarcoptes scabiei</i> (33) <i>Amblyomma variegatum</i> (48)	100% efficacy
Pig (Porcine)	10	Landrace	Female/ Adult	<i>Sarcoptes scabiei</i> <i>Scabiei</i> (10)	100% efficacy
Sheep (Ovine)	300	Yankasa	Female/ Adult	<i>Sarcoptes scabiei</i> <i>ovinae</i> (200) <i>Hyalomma/ Boophilus spp.</i> (100)	100% efficacy
Goat (Caprine)	200	Sokoto red	Female/ Adult	<i>Sarcoptes scabiei</i> <i>Caprine</i> (80) - <i>Boophilus decoloratus</i> (90) - <i>Amblyomma Variegatum</i> (50)	100% efficacy

REFERENCES

1. Alexander, J.O. (1984). Scabies. Arthropods and Human Skin. Berlin: Springer-Verlag. 422
2. Arial, G.L. (1989). Biology, Host relations, and Epidemiology of *Sarcoptes scabiei*. *Annual Review of Entomology*, (34) 139 – 61.
3. Bates, P.G. (1993). Alternative methods for the control of sheep scab. *Veterinary Record*, 133: 467 – 9.
4. Burgess, I. (1994). *Sarcoptes scabiei* and scabies. *Advances in Parasitology*, 33: 235 – 292.
5. Clymer, BC., Janes, TH., McKenzie, M.E.(1997). Evaluation of the therapeutic and protective efficacy of doramectin against psoroptic scabies in cattle. *Veterinary Parasitology* 72: 79 – 89.
6. Curtis, C.F.(2004). Current trends in the treatment of *Sarcoptes*, *Cheylepeiella* and *Otodectes* mite infestation in Dogs and Cats. *Veterinary Dermatology* 15:108 – 14.
7. Das S.S., Banerjee, P., Pandit, B., Bhatia, B. (1994). Use of Herbal compound against Sarcoptic mange in goats. *Tropical Animal Health Production*. 26: 117– 118.
8. Jongejan, F. and Uilenberg, G. (2004). The global importance of ticks, *Parasitology*, 129: S3–S14
9. Logan, N., Weatherley, AJ, Philiphs F.E.(1993). Spectrum of activity of doramectin against cattle mites and lice. *Veterinary Parasitology* 49: 67 – 73.
10. Mellaby, K. Epidemiology of scabies (1977). Philadelphia: Lippincott, 203.
11. Mellanby, K. (1985). Biology of the Parasite. New York: Dekker. 321
12. Mitra, M., Mahanta, S., Sen, S., Ghosh. C. and Hati, A.K., (1995). Transmission of *Sarcoptes scabiei* from animals to man and its control. *Journal of the Indian Medical Association* 93: 142-143.
13. Ogunsan, E.A., Dogo, G. I., Okewole P.A., Bello, M.K., Bwala, D. and Idachaba, D. (2006): Preliminary report on the efficacy of Scabicur preparation on the management and control of scabies and related maladies. *Vom Journal of Veterinary Science*, 1 (3): 44-48
14. Parish, L.C.(1977). History of scabies. Philadelphia: Lippincott, 1 -7.
15. Sekin S, Voyvoda, H., Testereci, H.(1996). Therapeutic efficacy of doramectin as a new endectocide on natural scabe and Trichostrongylose and changes for some blood parameters of Akkaraman sheep in Van. *Turkish Journal of Veterinary and Animal Sciences* 20: 325 – 30.
16. Soulsby E.J.L ed. (1982). Helminthes, Arthropods and Protozoa of Domesticated Animals. 7th ed. London. Bailliere Tindall, 482 – 6.
17. Voyvoda, H., Bulent U., Hasan, E., Tulin, K., and Goksel, B.(2005). Use of doramectin for treatment of Sarcoptic mange in five Angora rabbits. *Veterinary Dermatology* 16:285 - 288.