

## Case Report

# Primary ruptured ovarian pregnancy in a spontaneous conception cycle

Dalyop D. Nyango, Josiah T. Mutihir<sup>1</sup>, Silas O. Gbenga<sup>1</sup>

Departments of Obstetrics and Gynaecology, <sup>1</sup>Histopathology, Jos University Teaching Hospital, Jos, Nigeria

## Abstract

Ovarian ectopic pregnancy is an uncommon presentation of ectopic gestation, where the gestational sac is implanted within the ovary. Primary ovarian ectopic pregnancy is random and chance occurrence with estimated frequency ranging from 1 in 2 100 to 1 in 7 000 pregnancies. The diagnosis is seldom made clinically, that is, before surgery. Early detection permits removal of the ectopic pregnancy without excessive removal of healthy ovarian tissue. A case of acute abdomen that certified Spiegelberg's criteria at laparotomy and histological confirmation of ovarian pregnancy has been presented.

**Key words:** Ectopic, ovarian, pregnancy, ruptured

## Introduction

Ovarian pregnancy is an uncommon presentation of ectopic gestation, where the gestational sac is implanted within the ovary. It is a rare event, with estimates of frequency ranging from 1 in 2,100 to 1 in 7,000 pregnancies, or 3% of all ectopic pregnancies.<sup>[1]</sup>

The period of amenorrhea varies from none at all to several weeks, and rupture usually occurs before the end of the first trimester.

The diagnosis of an ovarian ectopic pregnancy is seldom made before surgery. This is because ovarian ectopic pregnancy is most commonly confused with a corpus luteum in an early or failing intrauterine pregnancy, tubal pregnancy, ruptured hemorrhagic corpora lutea, 'chocolate' cysts and ruptured tubal ectopic pregnancies, clinically, and pathologically. In addition, ovarian pregnancies can rarely be a part of heterotopic pregnancy.<sup>[2,3]</sup>

Although culdocentesis has been described in the evaluation of ovarian ectopic pregnancy, the role of transvaginal ultrasonography cannot be overemphasized.<sup>[4]</sup> The ultrasound dating in ovarian ectopic pregnancy lagged behind in comparison with the true gestational age of the woman.<sup>[5]</sup> The 'classic' findings described by Bradley *et al.*,<sup>[6]</sup> which differentiated the double ring of the decidua parietalis and capsularis of an intrauterine pregnancy gestational sac from that of a single ring of the pseudogestational sac of an ectopic pregnancy are not specific for ectopic pregnancy as they are often proved surgically to be tubo-ovarian or appendiceal abscesses. It is therefore, clear that the actual definitive demonstration of extra uterine gestational sac is rare, neither being specific nor sensitive enough to be relied on to diagnose this life-threatening process.<sup>[7]</sup>

Attempts to use color or spectral Doppler ultrasonography to reliably distinguish an ovariagestational sac from a corpus luteum have been unsuccessful, because overlaps with a corpus luteum has been high.<sup>[8]</sup> However, if a yolk sac or embryo can be seen within the sac, the diagnosis is established, but this is relatively infrequent.

Primary ectopic ovarian pregnancy is seen rarely. We described a histologically confirmed case of primary ovarian pregnancy in our institution in over a decade.

## Case Report

Mrs. NM was a 25-year-old woman who presented to

### Access this article online

#### Quick Response Code:



Website:  
[www.jmedtropics.org](http://www.jmedtropics.org)

DOI:  
10.4103/2276-7096.132580

### Address for correspondence:

Dr. Dalyop D. Nyango, Department of Obstetrics and Gynaecology, Jos University Teaching Hospital, Jos, Nigeria.  
E-mail: [dnyango@yahoo.com](mailto:dnyango@yahoo.com)

the gynecological outpatient clinic with amenorrhea of 43 days and lower abdominal pain of 2 weeks duration. She had anorexia and nausea, but no associated vomiting. She spotted severally 2 weeks prior to presentation, and no fainting attacks.

She was Gravida 4, Para 2+1 Both were normal vaginal deliveries, the only miscarriage was at 6 weeks gestation with no post abortal complications. She had not used any contraceptive method in the past.

Prior to presentation, she was evaluated for chronic renal disease at the Urology Unit. She was found to have bilateral hydronephrosis. Also, an ovarian cyst was noticed on ultrasound scan for which she was referred to the gynecological unit. She was a trader married to a Pastor.

Examination revealed an asthenic woman who was not pale and had no pitting pedal edema. Her pulse rate was 86/min and the blood pressure of 130/90 mm Hg. The lung fields were clear, with a respiratory rate of 14 cycles per minute. She had tenderness in the right iliac fossa region, but no guarding or rebound tenderness. A firm, tender, and freely mobile mass measuring 8 × 6 cm was felt over the suprapubic region. Vaginal examination showed healthy cervix and vagina and the uterus was about 10-week size; a tender mass was felt in the right fornix. The cervical movements were tender. Urine hCG test was positive.

Sonological findings showed right ovarian enlargement measuring 6.2 × 3.8 cm with mixed echogenicity. The left ovary was normal and measured 2.4 × 3.6 cm. The uterus was normal in size. There was moderate fluid collection in the pouch of Douglas. Both kidneys had increased echogenicity and enlarged, measuring 14.02 × 5.10 cm and 10.75 × 5.26 cm right and left respectively. However, the urea, electrolytes, and creatinine levels were within normal limits. The packed cell volume was 31% and the differential count was normal. The clinical diagnosis of ectopic pregnancy was made.

At laparotomy, the right ovary was enlarged, showing rupture of the tunica albuginea with necrotic tissue and adjacent yellowish corpus luteum. The left ovary appeared normal. Both fallopian tubes appeared normal and separate from the ectopic pregnancy [Figure 1]. The uterus was normal in size. A right oophorectomy was done. Her postoperative recovery was uneventful. The Packed Cell Volume on the second postoperative day was 34%.

The ovarian mass removed weighed 100 gm. The cut section showed soft darkish red hemorrhagic surface with some cystic foci containing jelly-like substance. No embryo was detected. The histological section showed fibroblastic stroma within which are seen several chorionic villi lined

by trophoblastic tissue and contain pale myxoid cores. Congested blood vessels with hemorrhage and necrosis in addition to chronic inflammatory cell infiltrate are also observed.

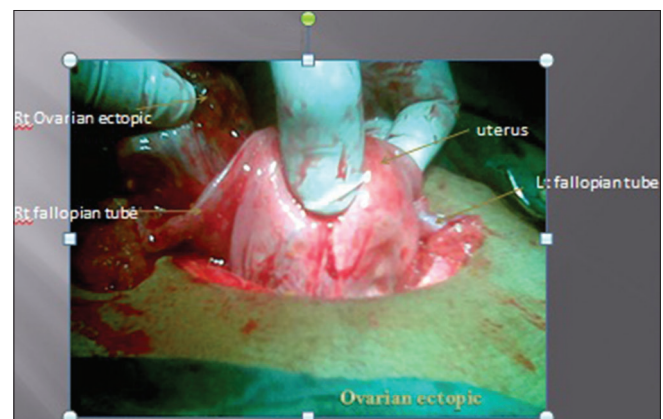
The diagnosis of ovarian ectopic pregnancy was made.

## Discussion

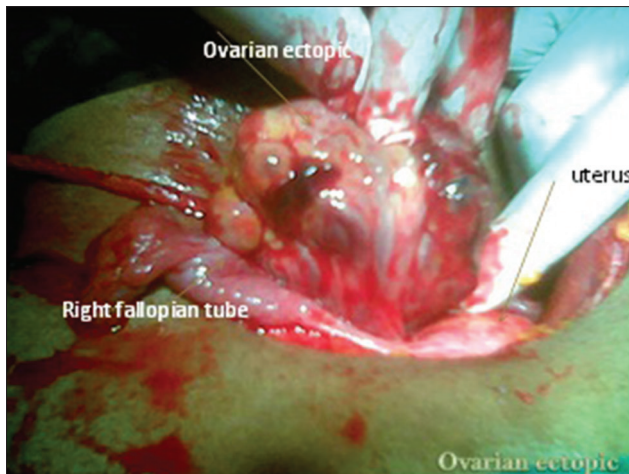
The diagnosis of ovarian pregnancy is seldom made before surgery. Most patients present with abdominal pain and light vaginal bleeding as early as 6 weeks, as seen in this case.<sup>[8]</sup> Ovarian pregnancy occurs in fertile patients in contrast with tubal pregnancy, which is most frequently associated with impaired fertility. This patient was however, subfertile. Both tubal and ovarian pregnancies have been strongly associated with the users of intrauterine contraceptive devices.<sup>[4]</sup> Though the uterine implantation of the fertilized ovum is sharply reduced by the use of such devices, there is no protection against pregnancies occurring elsewhere. This patient had not used IUCD. Marcus reported seven cases of ovarian pregnancy following *in-vitro* fertilization and embryo transfer.<sup>[9]</sup>

The modern methods of ultrasonography, laparoscopy, and estimation of human chorionic gonadotrophic (HCG) levels have been used in conjunction with repeated clinical evaluation in the diagnosis and management of extra uterine pregnancies in our institution. A positive urine beta-hCG in the absence of an intrauterine gestational sac on ultrasonography raised the suspicion of an ectopic pregnancy.

Spiegelberg's<sup>[10]</sup> criteria for an ovarian pregnancy are (1) Fallopian tubes, including fimbria, must be intact and separate from the ovary, (2) the pregnancy must occupy the normal position of the ovary, (3) the ovary must be attached to the uterus through the utero-ovarian ligament, and (4) there must be ovarian tissue attached



**Figure 1:** Bulky uterus with both fallopian tubes normal



**Figure 2:** The enlarged and highly vascularized ovarian pregnancy

to the pregnancy in the specimen. Fortunately, all these surgical criteria were established in this case [Figure 2], and confirmed at histology.

Early detection of an ovarian pregnancy prior to rupture of the gestational sac and onset of active bleeding permits laparotomy or laparoscopic surgery and removal of the ectopic pregnancy without excessive removal of healthy ovarian tissue. This is especially important in young patients who desire to maintain their reproductive capability. In this case, however, an oophorectomy was appropriate for such a ruptured gestational sac amidst increased vascularity of the ovarian tissue. Systemic methotrexate has been successfully used to treat ovarian ectopic pregnancy.

In conclusion, it is obvious that ovarian pregnancy is probably a random and a chance occurrence.

We reported a histologically confirm case of primary ovarian pregnancy from a tertiary institution in North Central Nigeria.

## References

1. Nadarajah S, Sim LN, Loh SF. Laparoscopic Management of an ovarian pregnancy; case report. *Singapore Med J* 2002;43:95-6.
2. Melilli GA, Avantario C, Farnelli C, Papeo R, Savona A. Combined intrauterine and ovarian pregnancy after *in vitro* fertilization and embryo transfer: A case report. *Clin Exp Obstet Gynecol* 2001;28:100-1.
3. Selo-Ojeme DO, Good Fellow CF. Simultaneous intrauterine and ovarian pregnancy following treatment with clomiphene citrate. *Arch Gynecol Obstet* 2002;266:232-4.
4. Herbertsson G, Magnusson SS, Benediktsdottir K. Ovarian pregnancy and IUCD use in a defined complete population. *Acta Obstet Gynecol Scand* 1987;66:607-10.
5. Comstock C, Huston K, Lee W. The Ultrasonographic Appearance of Ovarian Ectopic Pregnancies. In: *Principles and Practice of Obstetrics and Gynaecology Sonography*. In: Fleischer A, Manning F, Jeanty P, Romero R, Toy E, Lee W, editors. 7<sup>th</sup> ed., Vol. 105. New York: McGraw-Hill; 2011. p. 42-5.
6. Bradley WG, Fiske CE, Filly AA. The double sac sign of early intra-uterine pregnancy: Use in exclusion of ectopic pregnancy. *Radiology* 1982;143:223-6.
7. Romero R, Jeanty P, Hobbins JC. Diagnostic ultrasound in the first trimester of pregnancy. *Clin Obstet Gynaecol* 1984;27:286-313.
8. Stein MW, Ricci ZJ, Novak L, Roberts JH, Koenigsberg M. Sonographic comparison of the tubal ring of ectopic pregnancy with the corpus luteum. *J Ultrasound Med* 2004;23:57-62.
9. Marcus SF, Brinsden PR. Primary ovarian pregnancy after *in vitro* fertilization and embryo transfer: Report of seven cases. *Fertil Steril* 1993;60:167-9.
10. Spiegelberg O. Zur Cosuistik der Ovarialschwanger Schalt. *Arch Gynaekol* 1973;13:73-6.

**How to cite this article:** Nyango DD, Muthir JT, Gbenga SO. Primary ruptured ovarian pregnancy in a spontaneous conception cycle. *J Med Trop* 2014;16:42-4.

**Source of Support:** Nil, **Conflict of Interest:** None declared.

## Staying in touch with the journal

### 1) Table of Contents (TOC) email alert

Receive an email alert containing the TOC when a new complete issue of the journal is made available online. To register for TOC alerts go to [www.jmedtropics.org/signup.asp](http://www.jmedtropics.org/signup.asp).

### 2) RSS feeds

Really Simple Syndication (RSS) helps you to get alerts on new publication right on your desktop without going to the journal's website. You need a software (e.g. RSSReader, Feed Demon, FeedReader, My Yahoo!, NewsGator and NewzCrawler) to get advantage of this tool. RSS feeds can also be read through Firefox or Microsoft Outlook 2007. Once any of these small (and mostly free) software is installed, add [www.jmedtropics.org/rssfeed.asp](http://www.jmedtropics.org/rssfeed.asp) as one of the feeds.