

**Original article****Comparative morphologic and morphometric studies on the lower respiratory tract of adult Japanese quail (*coturnix japonica*) and pigeon (*columbia livia*)****S.A. Hena<sup>a,\*</sup>, M.L. Sonfada<sup>a</sup>, A. Bello<sup>a</sup>, A. Danmaigoro<sup>a</sup>, B.K. Tanimomo<sup>b</sup>**<sup>a</sup>Department of Veterinary Anatomy, Faculty of Veterinary Medicine, Usmanu Danfodiyo University, Sokoto, Nigeria<sup>b</sup>Department of Animal health and Production, Faculty of Veterinary Medicine, University of Abuja, Nigeria

\*Corresponding author; Department of Veterinary Anatomy, Faculty of Veterinary Medicine, Usmanu Danfodiyo University, Sokoto, Nigeria, Tel: +2348060524623

## ARTICLE INFO

*Article history:*

Received 17 August 2012

Accepted 26 August 2012

Available online 29 August 2012

*Keywords:*

Morphology

Morphometry

lower respiratory tract

## ABSTRACT

This study was concerned with the comparative evaluation of the morphologic and morphometric parameters of the lower respiratory tract of Japanese quail and that of pigeon. In the course of this work twenty birds (ten pigeons and ten Japanese quails) of both sexes were purchased from a poultry market in Sokoto metroplis, Sokoto, Nigeria and used. It was observed in this study that the lower respiratory tract extended from the caudal part of the oral cavity (around the larynx) down to the neck and to the thoracic region. The lower respiratory tract structures were the trachea (including the syrinx), the bronchus and the lungs. In the study, all the birds used were adults with mean body weight of 159.51±8.19g and 265.78±4.88g for the Japanese quail and pigeon respectively, this was considered extremely significant ( $P<0.05$ ). The tracheal weight, length and diameter in the quail were 0.55±0.06g, 7.61±0.37cm and 0.47±0.04 cm respectively, while the pigeon had 0.79±0.11g, 8.13±1.10 cm and 0.51±0.06 cm as corresponding values respectively. The morphometry of other respiratory apparatuses were obtained and presented. In both subjects the lungs were small, compact and non-expandable and were both found to be bright red in color and impregnated within the rib cage with contacts on their dorsal surfaces by the thoracic vertebrae in such a way that they delineated vertebral impression on the lung surfaces which resulted

in a division of the lungs into parts. The trachea was observed in both quail and pigeon to lie ventral to the esophagus along the length of the neck. There were complete tracheal rings comprising the windpipe and not C-shaped as in mammal, this probably is to provide better protection for the bird's trachea which needs to move freely subcutaneously due to the long cervical region and the ability of the bird to twist the neck through a wide range of motion. Both right and left bronchus were observed to have originated from the trachea in both species entering the left and right lobes of the lungs respectively. These informations could be useful in comparative anatomy, pharmacological and toxicological investigations, and as well as aiding in the understanding of the biology of these two bird types used in this study.

© 2012 Sjournals. All rights reserved.

---

## 1. Introduction

Japanese quails (*Coturnix japonica*) have been used as laboratory animals similar to rats and mice. They are reported to be more resistant to common pathogenic chicken diseases like Ranikhet disease, Coccidiosis etc. They have shorter generation interval and they yield quick return on low investment (Sreeranjini *et al.*, 2010). Quails are utilized as source of meat and egg with a particular belief of medicinal properties from these quail products more especially here in Nigeria. The pigeon (*Columbia livia*) is one of the commonest birds kept and bred by amateurs as ornamental birds, messenger and for meat purpose. It is a member of the bird family *Columbidea* comprising of the doves and pigeons (Gibbs *et al.*, 2007). They are robust, resistant to disease and easy to keep, requiring only simple cage and equipment and little space. Pigeon production is cheap as the pigeons are mostly kept on free range with only small boxes or houses, which accommodate them (Kigir *et al.*, 2010).

Although the respiratory system is relatively uniform among animals, certain morphologic, morphometric and physiological variations occurs in various species due to specificity in function and complexity (Reznik, 1990). A better knowledge of morphological norms and the causes of their variations are essential not only for a better understanding of physiology but also for a correct diagnosis and prognosis of diseases (Sarwar *et al.*, 1991). The respiratory system consists of organs that allow for a union between air and blood such that exchange of gases (mainly carbondioxide and oxygen) is made possible (Ibe *et al.*, 2008). The lower respiratory tract (LRT) is that part of the respiratory system that comprised of the trachea, syrinx (though in this study the syrinx was regarded as part of the trachea), the bronchus and the lungs as well as their associated structures.

Some studies had been conducted world wide extensively on the morphometric and gross anatomy of the respiratory system of avian species such as in chicken, turkey, ducks and geese, but little has been done concerning that of the Japanese quail and pigeon, more especially in the area of their comparative respiratory anatomy. The knowledge of the lower respiratory tract of the quail and pigeon would not only add to body of knowledge in anatomical literatures but would also be a step towards investigating the physiology of the respiratory system in these animal species studied.

## 2. Materials and methods

In the course of this work twenty birds (ten pigeons and ten Japanese quails) of both sexes were purchased from a poultry market in Sokoto metropolis, Sokoto state, Nigeria. Immediately after purchase, the birds were caged in well ventilated cages and transported by road to the Department of Veterinary Anatomy, Faculty of Veterinary Medicine, Usmanu Danfodiyo University, Sokoto. The birds were sedated lightly using chloroform as inhalant anaesthetic. The body weight (live weight) of each bird was obtained with a Digital Electronic balance (CITIZEN SCALES 1 PVT. LTD Model MP-600, with a sensitivity of 0.01g). The birds were then euthanized by an overdose of chloroform soaked on cotton wool and the bird put in an enclosed container. With the birds on dorsal recumbency an incision was made caudo-cranially from the vent to the shoulder joint on the lateral surface, the keel bone and

associated muscles were reflected to the opposite thereby giving access to the viscera. The location of the trachea and lungs were studied in-situ, then the organs were exteriorized, snapped using a digital camera (Samsung, ES10, 8.1 MEGA PIXELS) and their individual lengths determined using a thread which was stretched against the length of the organ to be measured from where the length of the thread was being matched to a ruler which was graduated in centimetre. The weights of the trachea and the lungs were also obtained in grams using the sensitive Digital Electronic balance (CITIZEN SCALES 1 PVT. LTD Model MP-600, with a sensitivity of 0.01g). The weights of the bronchus could not be measured due to their insignificant weights.

The data generated were subjected statistical analyses using the Microsoft Office Excel 2007 and GraphPad InStat statistical package, with values of  $P < 0.05$  considered significant.

### 3. Results and discussion

It was observed in this study (for both the quail and pigeon) that the lower respiratory tract extended from the caudal part of the oral cavity (around the larynx) down to the neck and to the thoracic region. The LRT is that part of the respiratory system that comprised of the trachea, syrinx, the bronchus and the lungs as well as their associated structures, though in this study the syrinx was considered as part of the trachea. The LRT structures used in this study were the trachea, the bronchus and the lungs.

In the study all the birds (quails and pigeons) used were adults. As shown in Table 2 the mean body weight of the Japanese quail was  $159.51 \pm 8.19$ g while that of the pigeon was  $265.78 \pm 4.88$ g, this was considered extremely significant statistically ( $P < 0.05$ ). Table 3 showed the mean total length, mean total weight and mean total diameter of the LRT features for the Japanese quail and Pigeon. The mean total weight of the LRT features for the quail was  $2.38 \pm 0.18$ g representing about 1.49% of the total body weight in the quail, while the mean total weight of the LRT for the pigeon was 4.03g representing 1.52% of the total body weight in the bird. The comparative percentage of the total weight of the LRT in both bird types were approximately 1.5% of their total body weights, this is in contrast to the findings reported by Ajayi et al., (2009) where they reported 1% as the weight of the LRT relative to the body weight in grasscutter. This higher weight percentage of the respiratory apparatus in these birds could probably be attributable to the fact that these birds are fliers and so must have higher demands placed on the respiratory system.

The trachea was observed in both quail and pigeon, to lie ventral to the esophagus along the length of the neck. From Table 1 the tracheal weight, length and diameter in the quail were  $0.55 \pm 0.06$ g,  $7.61 \pm 0.37$ cm and  $0.47 \pm 0.04$  cm respectively, while the pigeon had  $0.79 \pm 0.11$ g,  $8.13 \pm 1.10$  cm and  $0.51 \pm 0.06$  cm as the tracheal weight, length and diameter respectively. Though there are apparent differences in these parameters in both the quail and the pigeon, statistically there were no significant differences ( $P > 0.05$ ) between them across the two bird types studied. The mean tracheal diameter observed for both bird types in this study contrast the findings of Reznik, (1990) which reported 0.2 - 0.3 cm though in adult rats. There were complete tracheal rings comprising the windpipe (not C-shaped as in mammal). This probably is to provide better protection for the bird's trachea which needs to move freely subcutaneously due to the long cervical region and the ability of the bird to twist the neck through a wide range of motion.

Both right and left bronchus were observed to have originated from the trachea in both species entering the left and right lobes of the lungs respectively. The weights of the bronchi in both bird types were not taken as they were too insignificant to be measured; however, the lengths of both the right and left bronchus showed an extremely significant differences ( $P < 0.05$ ) between the quail and pigeon. The bronchial diameters were measured in both birds though the differences observed were not statistically significant ( $P > 0.05$ ). Choi et al. (2000) recorded a linear relationship between tracheal diameter and number of mucous glands in mammals and concluded that increased size of conductive airway (marked by increased tracheal diameter) results to an increased inflow velocity of inspired air which culminates in an increased rate of foreign body deposition.

Plates 1 and 2 showed the appearances of the quail and pigeon's LRT apparatus. In both subjects the lungs are small, compact and non-expandable. In this study the lungs of both quail and pigeon are both found to be bright red in color and impregnated within the rib cage with a contact on its dorsal surface by the thoracic vertebrae in such a way that they delineate vertebral impression on the lung surfaces. The weight, length and diameter (thickness) of the right lung in the quail were  $0.92 \pm 0.15$ g,  $2.26 \pm 0.13$ cm and  $0.66 \pm 0.04$ cm respectively while the counterpart values in the pigeon were  $1.53 \pm 0.28$ g,  $2.78 \pm 0.37$ cm and  $0.52 \pm 0.07$ cm respectively for the weight, length and diameter, all these were not however statistically significantly different ( $P > 0.05$ ).

The weight, length and diameter of the left lung in the quail were  $0.91 \pm 0.15$ g,  $2.29 \pm 0.14$ cm and  $0.73 \pm 0.03$ cm, while their corresponding counterpart values of the left lung in the pigeon were  $1.71 \pm 0.34$ g,  $2.61 \pm 0.36$ cm and  $0.52 \pm 0.07$ cm for the weight, length and diameter respectively. The weight and length of the left lungs were however not statistically significant but its thickness were considered statistically significant ( $P < 0.05$ ).

**Table 1**

Morphometric parameters of LRT features in Japanese quail and pigeon.

Parameter	JAPANESE QUAIL (n=10)			PIGEON (n=10)		
	Weight (g)	Length (cm)	Diameter (cm)	Weight (g)	Length (cm)	Diameter (cm)
Trachea	$0.55 \pm 0.06$	$7.61 \pm 0.37$	$0.47 \pm 0.04$	$0.79 \pm 0.11$	$8.13 \pm 1.10$	$0.51 \pm 0.06$
Right Lung	$0.92 \pm 0.15$	$2.26 \pm 0.13$	$0.66 \pm 0.04$	$1.53 \pm 0.28$	$2.78 \pm 0.37$	$0.52 \pm 0.07$
Left Lung	$0.91 \pm 0.15$	$2.29 \pm 0.14$	$0.73 \pm 0.03$	$1.71 \pm 0.34$	$2.61 \pm 0.36$	$0.52 \pm 0.07$
Right Bronchus	-	$0.46 \pm 0.34$	$0.31 \pm 0.03$	-	$1.47 \pm 0.10$	$0.29 \pm 0.04$
Left Bronchus	-	$0.45 \pm 0.03$	$0.31 \pm 0.03$	-	$1.48 \pm 0.09$	$0.31 \pm 0.04$

**Table 2**

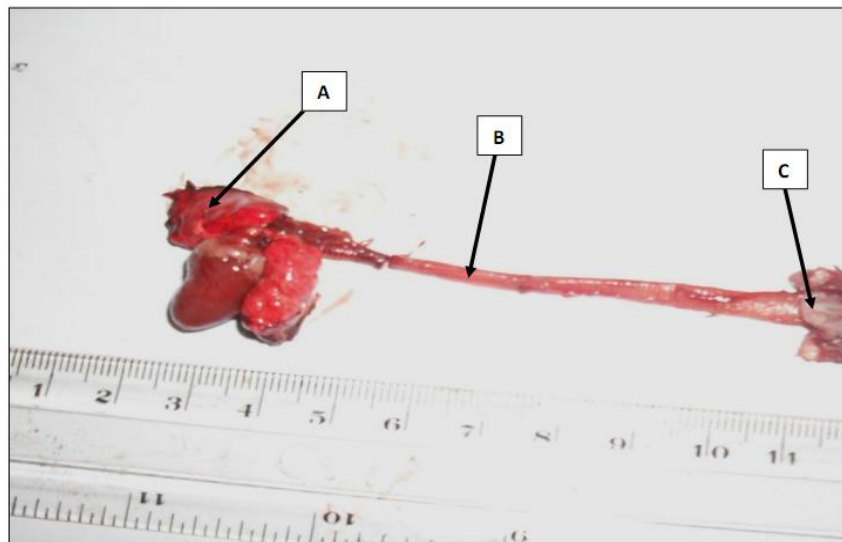
Body weights of Japanese quail and Pigeon

	Mean Body Weight	Minimum	Maximum
Quail (n=10)	$159.51 \pm 8.19$ g	128.2 g	202.3 g
Pigeon (n=10)	$265.78 \pm 4.88$ g	240.0g	285.0 g

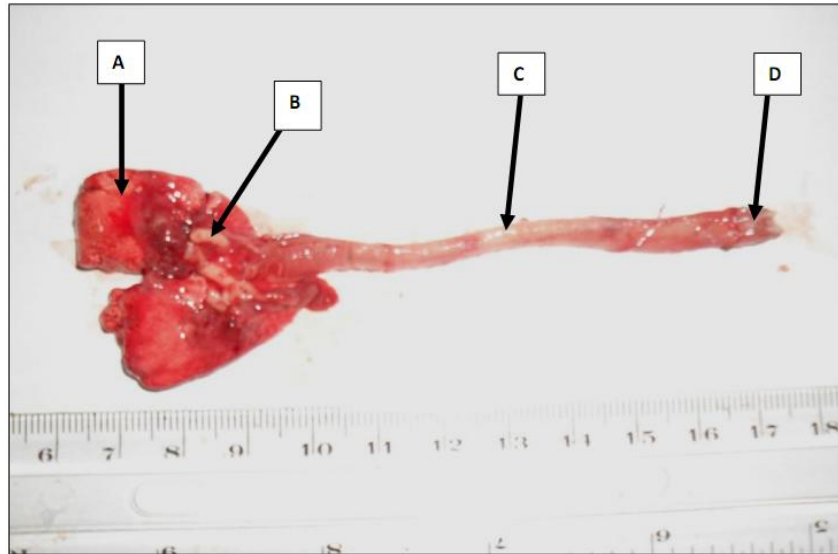
**Table 3**

The mean ( $\pm$ SEM) total length, weight and diameter of the LRT features for the Japanese quail and pigeon.

	Total Weight (g)	Total Length (cm)	Total Diameter (cm)
Quail	$2.38 \pm 0.18$	$13.07 \pm 0.72$	$2.48 \pm 0.32$
Pigeon	$4.03 \pm 0.21$	$16.47 \pm 1.02$	$2.15 \pm 0.11$



**Plate 1.** LRT of Japanese quail showing: Lung (A-arrow), Trachea (B-arrow) and Laryngeal mound (C-arrow) x125.



**Plate 2.** LRT of a pigeon showing: Lung (A-arrow), Bronchus (B-arrow), Trachea (C-arrow) and Laryngeal mound (D-arrow) x125.

The lung is a relatively rigid structure that does not expand and retract with breathing; its function is to provide a large surface area for gas exchange with the blood and it does this in a very small space. A very noteworthy observation made in both birds studied is the level of the entrenchment of each lung into the ribs which resulted in a division of the lungs into parts, this agrees with the findings reported by Ibe *et al.*, (2008) in guinea fowl. Maina and Nathaniel, (2008) also made similar observation in the ostrich. The lungs in both birds were compactly fitted against dorsal wall of thorax and they do not expand or contract this is in agreement to the work of Sakas, (2002). The general functions of the lungs are to provide for the exchange of gases, filtering of blood, and storage of blood from the right side of the heart before entering into systemic circulation. Also, metabolic functions which the lungs perform include the processing of proteins and lipids, activation or inactivation of hormones, and processes involved in the metabolism of xenobiotic compounds which may reach the lungs via the airways or through the vasculature. The lungs of birds are relatively small, but are connected to 8-9 air sacs that extend through much of the body, and are in turn connected to air spaces within the bones. Though birds have smaller lungs per unit body mass than mammals by a factor of 27% (Maina *et al.* 1989), the rigidity of the avian lung has permitted substantial increase in the respiratory surface area by intense internal subdivision.

#### 4. Conclusion

It could generally be implied in this study that though, in absolute terms, there are some differences in the morphologic as well as the morphometric features of the LRT of the quails and pigeons used in this studies, in relative terms there are few morphological as well as morphometrical differences in their LRT apparatuses. The pigeon had slightly higher values in most organs related to this study which could probably be as a result of the nature of flight of this bird type, being a higher and longer flier than the quail, and as such having much demands placed on the functional anatomy of the LRT. In this study we had attempted to present findings comprising the comparative morphologic and morphometric observations on the lower respiratory tract on Japanese quail and that of the pigeon. These informations could be useful in comparative anatomy, pharmacological and toxicological investigations, and as well as aiding in the understanding of the biology of these two bird types used in this study.

#### References

- Ajayi, I.E., Salami, S.O., Danjuma, F.A., Ayo, J.O., Ibe, C.S., Ojo, S.A., 2009. Morphologic and morphometric studies of the lower respiratory system of the grasscutter (*Thyromys swinderianus*). In: The proceedings of the 46<sup>th</sup> Annual congress of the Nigerian Veterinary Medical Association "Anambra 2009" ISSN:0331-3026. Pp 1-5.

- Choi, H.K., Finkbeiner, W.E., Widdicombe, J.H.A., 2000. Comparative study of mammalian tracheal mucous glands. *J. Anat.* 197, 361-372.
- Gibbs, D., Eustace, B., John, C., 2007. Pigeon and Doves. A Guide to the Pigeons and Doves of the World. United Kingdom: Pica Press. Pp 624. ISBN 1873403607.
- Ibe, C.S., Onyeanus, B.I., Salami, S.O., Umosen, A.D., Maidawa, S.M., 2008. Studies of the major respiratory pathways of the West African guinea fowl (*Numida meleagris galeata*): the morphometric and macroscopic aspects. *Inter. J. Poult. Sci.* 7(10), 997-1000.
- Kigir, E.S., Sivachelvan, M.N., Kwari, H.D., Sonfada, M.L., Yahaya, A., Thilza, I.B., Wiam, I.M., 2010. Gross and Microscopic Changes in the Gonads of Male and Female Domestic Pigeon (*Columbia Livia*). *New York Science Journal* 3(10)108-111.
- Maina, J.N., King, A.S., Settle, G., 1989. An allometric study of the pulmonary morphometric parameters in birds, with mammalian comparison. *Phil. Trans. Royal Soc., London B* 326, 1-57.
- Maina, J.N., Nathaniel, C., 2008. A qualitative and quantitative study of the lungs of an Ostrich, (*Strutho camelus*). *J. Experimental Biol.* 204, 2313-2330.
- Reznik, G.K., 1990. Comparative anatomy, physiology and upper respiratory tract. Retrieved from <http://www.ehponline.org/members/1990/85023.PDF>.
- Sakas, P.S., 2002. Basic Avian Anatomy. In: *Essentials of Avian Medicine: A Guide for Practitioners*, Second Edition. Published by the American Animal Hospital Association Press.
- Sarwar, A.M.N., Chaudhary, I.R., Khan, S.A., Majeed, M.A., 1991. Eight serum biochemical values of one-humped camel (*Camelus dromedarius*) in summer: Effect of sex, age in males and lactation and pregnancy in females. *Pakistan Vet. J.* 11(2), 62-68.
- Sreeranjini, A.R., Iyyangar, M.P., Pramodkumar, D., 2010. Histological study on the fibrous architecture of kidney and ureter of Japanese quail (*Coturnix coturnix japonica*). *Tamilnadu J. Vet. Anim. Sci.* 6 (2), 107-110.