

Childhood acute appendicitis: Is routine appendicectomy advised?

A. F. Uba, L. B. Lohfa, M. D. Ayuba¹

Departments of Surgery and ¹Pathology, Jos University Teaching Hospital, P.M.B. 2076, Jos, Plateau State, Nigeria

Correspondence: A. F. Uba, Paediatric Surgery Unit, Department of Surgery, Jos University Teaching Hospital, P.M.B. 2076, Jos, Plateau State, Nigeria. E-mail: afranu@yahoo.com

ABSTRACT

Acute appendicitis is a common occurrence in children. The current trend is to perform appendicectomy once acute appendicitis is diagnosed. The aim of this study was to evaluate the types of pathology seen in appendices removed for acute appendicitis and correlate them with clinical features. The clinical, operative and histological records of 302 children who had appendicectomy at the Jos University Teaching Hospital from 1995-2003 were retrospectively reviewed. There were 123 (40.7%) boys and 179 (59.3%) girls (m: f = 1: 1.5). Their ages ranged from 2-15 years (median: 12 years). The main symptoms and signs at presentation were right lower quadrant abdominal pain, anorexia, nausea, vomiting, right quadrant tenderness, guarding and rigidity. Clinical impressions included simple acute appendicitis in 260 and perforated appendicitis in 42 patients. Of the 302 children who had clinical diagnosis of acute appendicitis, only 144 (47.7%) were confirmed at histology. Lymphoid hyperplasia was the most common pathology seen in the appendix specimens. The clinical impressions of acute appendicitis made by the surgeon agreed with pathologists' report in 63.9% and disagreed in 36.1% of cases. Negative appendicectomy rate was 52.3%. Although appendicectomy is the most commonly performed emergency abdominal surgery in children, the procedure is still associated with a high negative appendicectomy rate.

KEY WORDS: Acute appendicitis, children, diagnosis, negative appendicectomy rate

Appendicitis is the most common nontraumatic surgical abdominal emergencies in children.^[1] However, the clinical diagnosis of childhood appendicitis continues to pose difficulty,^[2] and this has resulted in unnecessary surgery, or a missed appendicectomy in many series. Proportion of appendices that are normal on histologic examination attests to this problem. In many series, negative appendicectomy rate is in the range of 10-30%.^[3-5] Auditing of appendicectomy based on the analysis of histologic findings, clinical features and macroscopic appearance of the appendix at operation should serve as a quality control in the surgery of childhood acute appendicitis.

In the present study, we evaluated the extent to which clinical features and macroscopic appearance of appendix at surgery agree with histologic findings in the diagnosis of childhood appendicitis managed in our hospital over a 10-year period.

MATERIALS AND METHODS

This study was a retrospective review of children that had appendicectomy at the Jos University Teaching Hospital

between 1994 and 2003. Cases of appendix abscess and appendix mass were excluded from this analysis. The data were collated from the patients' case files, operation registers and histopathologic registers and analyzed for the clinical features, type, histological analysis of acute appendicitis and outcome. All the histologic slides were reviewed by consultant pathologists. Surgeons' assessment of the appendix based on macroscopic appearance was compared with the pathologist's histologic assessment (which is assumed to be the more accurate). The data was analyzed, using EPI Info version 6.

RESULTS

A total of 302 children had appendicectomy for clinically diagnosed acute appendicitis at JUTH over the 10-year period. Twenty three and 35 children were managed for appendix mass and abscess, respectively. These children later had interval appendicectomy and are also included in this study.

Their ages ranged from 2-15 years (median: 12). There were 123 (40.7%) boys and 179 (59.3%) girls (m: f = 1: 1.5). The peak incidence of appendicitis was in the

age group of 10-14 years [Figure 1]. Forty-four (14.6%) of the children were below 5 years of age. Majority of the patients presented within 24 hours after the onset of the acute symptoms. Admissions for appendicitis constituted 2.5% of all admissions in children within the same period and appendectomy accounted for 62% of emergency abdominal operations performed at the same time. The yearly cases of childhood appendectomy within the period are shown in [Figure 2].

The main features at presentation were right lower quadrant abdominal pain, tenderness, guarding, rigidity, nausea, anorexia and vomiting [Table 1]. Clinical impressions included simple acute appendicitis in 260 and perforated appendicitis in 42 patients. Operative findings suggested simple acute appendicitis in 226, normal appendices in 40, perforated appendicitis in 36 patients, out of which 24 were gangrenous. Faecoliths was present in 61 appendices.

Of the 302 appendices, 144 (47.7%) were confirmed inflamed at histology, while 158 (52.3%) were not. Thus the negative appendectomy rate was 52.3%. Sixty two (39.2%) of the uninflamed appendices had no recognizable pathology, while 96 (60.8%) showed

Table 1: Symptoms and signs of childhood appendicitis in JUTH in the year 1994-2003

Features	No. with appendicitis (n = 144) N (%)	No. without Appendicitis (n = 158) N (%)
<i>Symptoms</i>		
Right lower quadrant pain	144 (100)	158 (100)
Anorexia	110 (76.4)	95 (60.1)
Nausea	96 (66.7)	70 (44.3)
Vomiting	88 (61.1)	52 (32.9)
Fever	65 (45.1)	74 (46.8)
<i>Signs</i>		
Right lower quadrant tenderness	144 (100)	130 (82.3)
Rigidity	98 (68.1)	142 (90.5)
Guarding	96 (66.7)	42 (26.6)
Abdominal distension	24 (16.7)	8 (5.1)

lymphoid hyperplasia and/ or faecoliths (16/96).

In the inflamed group, 45 appendices (including 25 perforated and gangrenous appendices) contained faecoliths while 58 had lymphoid hyperplasia. One hundred and eight (75%) of the inflamed appendices were uncomplicated while the remaining were complicated by either perforation (36) or gangrene (24/36). Ten other children had resolving appendicitis, characterized by mucosal ulceration and granulation tissue with an abundant infiltration of eosinophils.

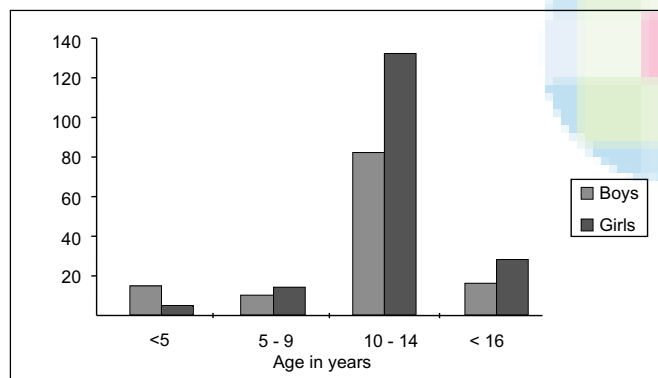


Figure 1: Age and gender distribution among 302 children who underwent appendectomy at JUTH in the year 1994-2003

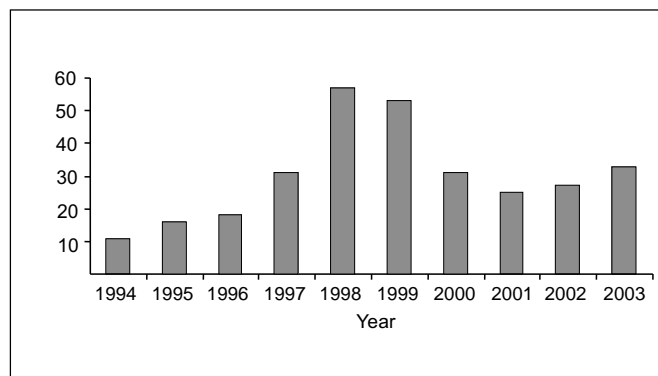


Figure 2: Yearly appendectomy in childhood at JUTH between 1994 and 2003

Clinical and histopathological impressions on appendices in children made by the surgeon and pathologist agreed in 63.9% and disagreed in 36.1%. The diagnosis was overrated in 19.6% (exclusively by the surgeons) and underrated in 16.5% of cases (16.3% by surgeons and 0.2% by the pathologist). Twelve (19.4%) of the 40 appendices which surgeons thought to be normal were discovered to be inflamed at histology.

Postoperative complications occurred in 54 (17.9%) patients. Surgical site infection (SSI) occurred in 30 (9.9%) patients, partial revealed wound dehiscence in 18 (6.0%), residual intraperitoneal abscesses in 13 (4.3%), intractable/recurrent right iliac fossa pain in 8 (2.6%) and adhesive intestinal obstruction in 6 (2.0%). Postoperative complications are shown in [Table 2]. Over 81% of the complications occurred in the patients operated for perforated/gangrenous appendicitis with local or generalized peritonitis. The SSI was managed by antibiotics, while residual abscesses were drained by laparotomy. The dehisced wounds were closed secondarily after the infections were controlled. The adhesive intestinal obstruction was satisfactorily managed nonoperatively. The overall mortality rate was 9 (3.0%), all of which was in the perforated group. The causes of death were faecal fistula in 2 and overwhelming infection in 7 patients.

Table 2: Postoperative complications in 302 children who underwent appendicectomy at JUTH in the year 1994-2003

Postoperative complications	Uncomplicated Appendicitis	Perforated appendicitis	Gangrenous appendicitis
	(n = 242) X (%)	(n = 36) X (%)	(n = 24) X (%)
Surgical site infection	4 (1.7)	19 (52.7)	7 (29.2)
Superficial reveal wound dehiscence	-	16 (44.4)	2 (8.3)
Residual intraperitoneal abscess	-	9 (25.0)	4 (16.7)
Faecal fistula	6 (2.5)	4 (11.1)	2 (8.3)
Intractable right iliac fossa pain	5 (2.1)	2 (5.6)	1 (4.2)
Adhesive intestinal obstruction	2 (0.8)	6 (16.7)	-

DISCUSSION

The negative appendicectomy rate in this report was very high compared with other results.^[6-8] A number of reasons could possibly be responsible for this. First, a significant number of appendicectomies was performed for appendices that showed only lymphoid hyperplasia without histological evidence of inflammation. 'Lymphoid hyperplasia' is characterized by 'swollen' (increase in size of) lymphoid tissue which is due to immune reaction to immunological challenges like viral infection. It has been speculated the presence of lymphoid hyperplasia alone can cause symptoms, even in those organs that show no morphological abnormalities/inflammation on histological examination.^[9] What is obvious is that obstruction of the lumen of the appendix by lymphoid hyperplasia is important in the pathogenesis of acute appendicitis.^[9,10] Clinically it is difficult to differentiate lymphoid hyperplasia from real infection of the appendix, unless at histology.

Secondly, it was possible that some of the appendicectomies were erroneously performed for other causes of abdominal pains in childhood rather than appendicitis. In a report by Boerema et al. 7.3% of their patients erroneously had appendicectomies for various other causes of abdominal pains.^[10] It is possible that if we had used preoperative laparoscopy,^[11-13] ultrasonography^[14] or computerized tomography,^[15] such error would have been avoided. At the time of this study, however, we lack experience with the use of these diagnostic modalities in appendicitis and so we relied only on clinical findings and this could have contributed to the high negative appendicectomy rate observed.^[16,17]

Appendicectomy-related admissions constituted 2.5% of all children admissions and more than two-thirds of all childhood abdominal surgical emergencies in this report. Childhood acute appendicitis remains a common surgical problem. Our study showed that the clinical and macroscopic assessment of acute appendicitis agreed with histologic findings in the diagnosis of childhood

appendicitis only in 63.9% of cases. This finding compares favourably with that of Geryk et al.^[18] One hundred and fourteen (37.7%) appendices deemed inflamed by the surgeon were histologically normal while 80 (26.5%) of those deemed normal by the surgeon were actually inflamed at histology. This underscores the limitedness of diagnosing acute appendicitis by appearance.

The rate of uncomplicated appendicitis (75%) seems high in this report. A possible explanation is that most of the patients presented early and had their operations before complications could set in.

The number of negative or unnecessary appendicectomies is from the pathologist's point of view significantly higher than from the surgeons' point of view. This compares with a report by Wright and colleague,^[4] in which 8.7% of appendices deemed normal by the surgeon were histologically inflamed and 3.5% of those deemed inflamed by the surgeon were histologically normal. Most (22.5%) of the inflamed appendices in study showed lymphoid hyperplasia as in the report Babekir and associate.^[19]

Operation is not mandatory if you have sonographic signs: adenolymphitis - no inflammation of surrounding fat and hyperplasia of the mucosa. Clinically that is difficult to differentiate from real infection. So if you had no sonographic tools this type of appendicitis is to put in the positive appendectomies. In view of the unacceptably high negative appendicectomy rate observed in children, a watchful nonoperative management involving intravenous fluid infusion, antibiotics and nothing by mouth policy in children with uncomplicated appendicitis has been suggested.^[6,20]

We like to conclude that although appendicectomy is the most commonly performed emergency abdominal surgery in children, the procedure is still associated with a high negative appendicectomy rate if diagnosis is based solely on clinical features.

REFERENCES

1. Ozguner IF, Buyukayavuz BI, Savas MC. The influence of delay on perforation in childhood appendicitis. A retrospective analysis of 58 cases. *Saudi Med J* 2004;25:1232-6
2. Balthazar EJ. Appendicitis: Prospective evaluation with high resolution CT. *Radiology* 1991;180:21-4.
3. Gough IR, Morris MI, Pertnikovs EI, Murray MR, Smith MB, Bestmann MS. Consequences of removal of a "normal" appendix. *Med J Aust* 1983;16:370-2.
4. Wright JE, Rowley M. Appendectomy in childhood: pathology found. *Aust N Z J Surg* 1987;57:381-5.
5. Rothrock SG, Skeoch G, Rush JJ, Johnson NE. Clinical features of misdiagnosed appendicitis in children. *Ann Emerg Med* 1991;20:45-50.
6. Surana R, O'Donnell B, Puri P. Appendicitis diagnosed following active observation does not increase morbidity in children. *Pediatr Surg Int* 1995;10:76-8
7. Pearl RH, Hale DA, Molloy M, Schutt DC, Jaques DP. Pediatric appendectomy. *J Pediatr Surg* 1995;30:173-81.
8. Douglas CD, Macpherson NE, Davidson PM, Gani JS. Randomised controlled trial of ultrasonography in diagnosis of acute appendicitis, incorporating the Alvarado score. *Br Med J* 2000;321:919-22.
9. Chang AR. An analysis of the pathology of 3003 appendices. *Aust NZ Surg* 1981;51:163-78.
10. Boerema WJ, Burnand KG, Fitzpatrick. Acute appendicitis. *Aust NZ Surg* 1981;51:163-78.
11. Goh BK, Chui CH, Yap TL, Low Y, Lama TK, Alkouder G, et al. Is early laparoscopic appendectomy feasible in children with acute appendicitis presenting with an appendiceal mass? A prospective study. *J Pediatr Surg* 2005;40:1134-7.
12. Blanco JA, Casasa JM, Castellvi A, Isnard RM, Lopez P. [Laparoscopy in chronic abdominal pain in children] [Article in Spanish] *Cir Pediatr* 2005;18:61-4.
13. Al-Bassam AA. Laparoscopic appendectomy in children. *Saudi Med J* 2005;26:556-9.
14. Kaneko K, Tsuda M. Ultrasound-based decision making in the treatment of acute appendicitis in children. *Pediatr Surg Int* 2004;39:1316-20.
15. Rhea JT, Halpern EF, Ptak T, Lawrason JN, Sacknoff R, Novelline RA. The status of appendiceal CT in an urban medical center 5 years after its introduction: experience with 753 patients. *AJR Am J Roentgenol* 2005;184:1802-8.
16. Samuel M. Pediatric Appendicitis Score. *J Pediatr Surg* 2002;37:877-81.
17. Kharbanda AB, Taylor GA, Fishman SJ, Bachur RC. A clinical decision rule identify children at low risk for appendicitis. *Pediatrics* 2005;116:709-16.
18. Geryk B, Kubikova E, Jakubovsky J. (Abstract) Clinical and histopathologic picture of acute appendicitis in children. *Rozhl Chir* 2000;79:211-4.
19. Babekir AR, Devi N. Analysis of the pathology of 405 appendices. *East Afr Med J* 1990;67:599-602.
20. Ludtke FE, Muller B, Peiper HJ. (Abstract) Indications for appendectomy: A retrospective analysis. *Zentralbl Chir* 1987;112:1545-51.

